

FEEDING THE HOOF

Eleanor M. Kellon, V.M.D.
Equine Nutritional Solutions
Ephrata, Pennsylvania
USA
www.drkellon.com

Much of the information below is extracted from materials in either my Nutrition as Therapy or Cushing's and Insulin Resistance courses. Before getting to that, I just want to mention that feeding for hoof health is no different than feeding for health in general. There are no magical nutrients for hoof health.

Every cell in the horse's body is like a tiny battery powered factory. Like all batteries it depends on a very specific balance of ions (minerals) to operate. The factory is fueled by calories in the form of carbohydrates, fats, protein and fermentation products from the hindgut and it uses these to manufacture the products it needs – enzymes, membranes, proteins of many types.

Horses are able to interconvert fats, carbohydrates and even amino acids (the building blocks of protein) to some extent. They can increase active absorption of minerals when they have a need, and are equipped with mechanisms to excrete excess minerals except iron. However, there are certain amino acids and fatty acids they cannot manufacture. These are termed “essential” because it is essential for them to be in the diet. Similarly, they cannot manufacture minerals from thin air. There are minimum requirements they must take in. This is complicated by the fact that minerals can compete for absorption inside the intestines.

I personally feel there are more hoof health issues caused by poor trimming and hoof mechanics than nutrition. That said, there are several very common deficiencies that impact the feet.

Skin, coat and hooves all have the same major structural protein – keratin. There's keratin, and then there's keratin! In humans to date, 54 genes have been identified that code for a type of keratin.

Keratin, like all proteins, is a strand of **amino acid** units. Alanine, glycine and the sulfur containing amino acid cysteine (produced from methionine) are the primary amino acids in keratin.

Alpha-keratin (below) is the predominant keratin found in mammalian tissue, from hair to hoof horn. Beta-keratin is tougher keratin found in the outer skeletons of insects but may also occur to some extent in mammalian tissue, like human fingernails. The tubular/helix structure of alpha keratin is carried over into the larger structural unit of horn tubules in the hoof wall.

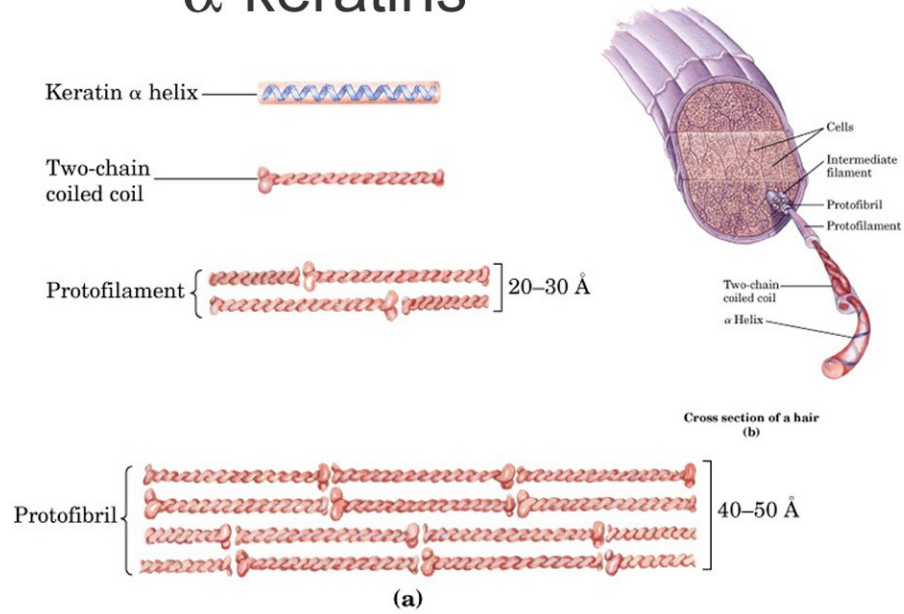
© 2008 Eleanor M. Kellon, VMD

Since the hoof wall is well over 90% protein when all water is removed, it's worthwhile talking about the keratin a little bit more. As above, alanine and glycine are in abundance. These are nonessential amino acids easily generated from other nutrients including end products of carbohydrate metabolism and branched chain amino acid metabolism. This reaction requires pyridoxine (B6).

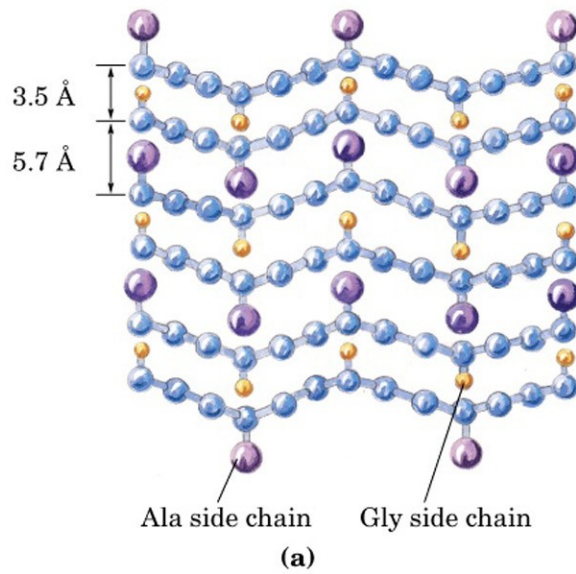
We can now identify several dietary factors that may limit hoof quality on the protein end of things:

- Methionine deficiency
- Branched chain amino acid deficiency (unlikely except with heavy work).
- Protein deficiency in general
- Inadequate vitamin B6

α -keratins



β -keratins

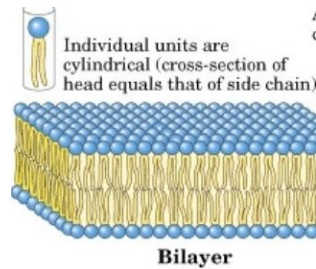


Structure of Keratins
Ala = alanine, Gly = glycine.

© 2008 Eleanor M. Kellon, VMD

The outermost layer of the hoof wall (stratum externum, aka periople) also contains a variety of **fats** and waxes, as does the “hard”/dead portion of the hoof wall in general. The stratum externum grows down from the epithelial cells of the periople, located below the coronary band. The hardest layers of the external hoof have the highest molecular weight keratin. Equally important are the fatty substances. When present in correct amounts in an unbroken layer, these seal moisture into the deeper hoof structures and seal water out.

The major fat is cholesterol sulfate, which is a polar lipid. Like the phospholipids in cell membranes (NRC Plus), these molecules will form a double layer. “Polar” means one end is attracted to fat, the other end to water. These molecules line up with their fat loving/water hating tails facing each other and their water loving heads exposed to the outside and inside. Other polar phospholipids (the ceramide family) are also present. The “soft” horn – white line area – has less fat and more squalene. Squalene is a precursor for cholesterol. It's higher levels in this area may mean that it contributes to cholesterol in the horn, or the higher squalene could also result in a softer, more fluidy trap around the cells, allowing the growing hoof wall to slide down easier.



Lipid Bilayer

Polar, “water loving” heads on the outside.

Fatty tails on the inside preventing moisture from leaving or entering.

The various fats and waxes fill the spaces between the keratinocytes, the cells producing keratin. They give the outer layer of a healthy hoof a naturally slick feel and shine.

There's no problem with synthesizing any amount of cholesterol, or the phospholipids and other fatty substances in the hoof so “fat deficiency” per se is not an issue. However, we do know that alteration of dietary fats can change the composition of the fats in the hoof wall:

[Equine Vet J Suppl.](#) 1998 Sep;(26):58-65.

Effect of a supplementary dietary evening primrose oil mixture on hoof growth, hoof growth rate and hoof lipid fractions in horses: a controlled and blinded trial.

[Reilly JD](#), [Hopegood L](#), [Gould L](#), [Devismes L](#).

Royal Army Veterinary Corps, Defence Animal Centre, Melton Mowbray, Leicester, UK.

The lipid chemistry of the normal equine hoof, together with the effect of oral supplementation with an evening primrose oil mixture (EPOM) on its growth, growth rate and lipid content was assessed in a controlled and blinded feeding trial at the Defence Animal Centre. Twelve horses were paired as closely as possible according to sex, age, weight, height and colour and then one from each pair was randomly allocated to treatment or control groups. The treatment group received 30 ml of oral EPOM/day, otherwise the nutrition and management regimes were the same for all horses. No significant differences ($P > 0.05$) were seen between treatment and control groups for hoof horn growth or growth rate. However, there was a significant difference ($P < 0.05$) in hoof horn growth within the treatment group only between weeks 4 and 8 after the start of supplementation. The stratum medium contained significantly higher amounts of cholesterol ester ($P < 0.05$), triglycerides ($P < 0.001$) and free fatty acids ($P < 0.05$) than the periople. The periople contained significantly higher levels of free cholesterol and phospholipid ($P < 0.001$) than the stratum medium of the hoof wall. There were no significant differences ($P > 0.05$) between treatment and control groups for any of the lipid fractions measured for the stratum medium from the clippings of the hoof wall. However, there were differences in perioplic lipid analysis with significant increases ($P < 0.05$) in cholesterol esters and partial glycerides and a significant reduction ($P < 0.001$) in free cholesterol in the treatment group following supplementation.

It's not immediately obvious from that study whether the changes found were a good or a bad thing, or of no consequence. However, they do show the composition of fats in the diet will influence this important component of the hoof wall. What we need are long term studies looking at fat from all sources on various diets, including grazing, then comparing this to hoof wall quality.

When in doubt because information is lacking, I personally tend to fall back on what the horse's natural diet would provide as the likely optimum. This means predominantly grass, which is a rich source of the essential fatty acids linolenic (omega-3) and linoleic acid (omega-6) in a ratio of from 4:1 to 6:1. Working with mother nature tends to be a lot more productive than thinking you can outwit her. For horses on green pasture, forget about supplemental fat in any form. For horses on hay based diets, it surely can't hurt to supplement them with what they are missing from this dried grass – the essential fatty acids. This means 4 to 6 ounces per day of freshly ground or ground stabilized flax. Only flax seed (and a few other rare seed varieties) provides the essential fatty acids in the same ratios as grass. Omega-6 fats are very proinflammatory. These predominate in grains, vegetable oils and commonly fed seeds or nuts.

The role of **minerals** really has not been studied in horses, but we do know a few things from studies in cows. Calcium is required for activation of an enzyme called epidermal transglutaminase. This enzyme is involved in the transformation of skin/epithelial cells into the keratinocytes that form hoof horn. It is also necessary to form crosslinks between keratin fibers. Hypocalcemia has been suggested as a possible cause for rings that often form in cows' feet around the time of calving and the start of heavy milk production.

© 2008 Eleanor M. Kellon, VMD

Mares that are heavy milkers could also be experiencing some hypocalcemia when they are in early lactation. It's certainly true that mares do indeed often show hoof rings that correspond to foaling and early lactation. Another possibility is hormonal influences though (below). Inadequate dietary calcium would not be expected to cause any effects because calcium would be mobilized from bone to compensate. Prolonged alkalosis (high blood pH) of at least several days could theoretically reduce calcium availability enough to influence the hoof (eg horse being worked heavily every day in high heat with inadequate chloride intake) and fluorosis has documented effects on the feet:

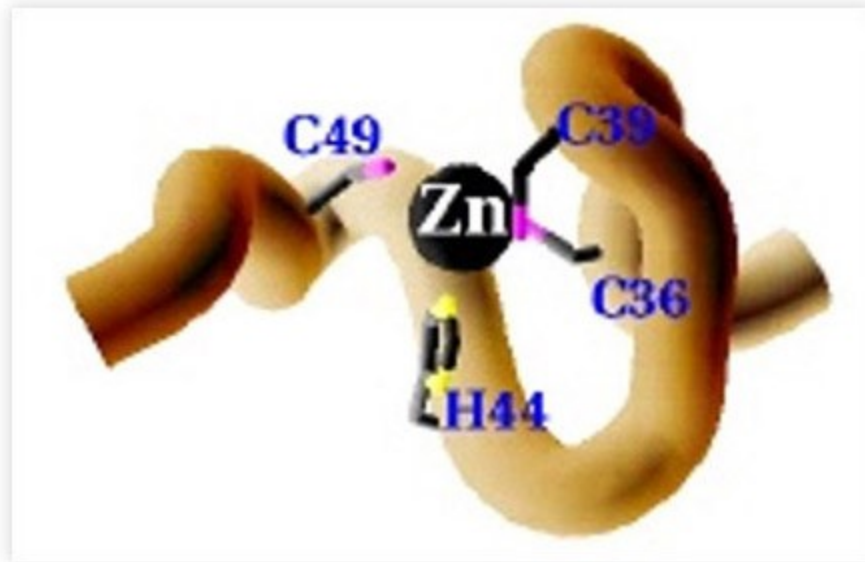


Severe Hoof Deformity from Fluoride Poisoning

The likelihood of a horse having fluoride poisoning is pretty slim, but it does drive home the role that calcium plays in hoof health since the changes of fluoride poisoning are caused by fluoride substituting for calcium.

© 2008 Eleanor M. Kellon, VMD

Zinc is present in high concentration in normal hoof tissue (137 ppm in one study), and is critical for a variety of functions.



Zinc Finger Protein

Zinc incorporated into zinc finger proteins (named because of their shape) is required for cell multiplication, cell maturation into a keratinocyte and for interactions between proteins, such as the assembly of keratin. Zinc finger proteins also are rich in cysteine. Zinc proteins incorporated into keratin are also for the helical structure.

Zinc is also essential for a variety of enzymes that every metabolically active cell needs and is involved in regulating the rate of cellular division, cellular activity and cellular maturation. For example, zinc regulates the activity of calmodulin. Calmodulin is what binds calcium. With all the functions that require zinc, it's not too difficult to see how zinc deficiency will show up in a variety of ways in the hoof:

- Slow hoof growth
- Thin walls
- Weak connections
- Weak horn

When the hoof is weak at the cellular and structural level, it is more vulnerable to attack by organisms because even “micro breaks” in the structure will allow microbes in. There's more to it though, and this involves zinc too, as well as copper. Copper/zinc superoxide dismutase enzyme is present in hoof tissue and its function is to prevent the fats and oils from oxidizing. Oxidative damage to the fats breaks the

© 2008 Eleanor M. Kellon, VMD

protective seal on the hoof, causing overdrying, and weakens the “glue” between the cells.

Copper is also involved in enzymes required for aerobic metabolism in rapidly dividing cells, and is required for the activation of the enzyme which forms the sulfur crossbridges that hold keratin strands together.

In cattle, deficiencies of either copper or zinc have been linked to:

- Soft feet
- Cracks
- Sole hemorrhages
- Abscesses
- Thrush (“foot rot” in cattle)
- Laminitis

while supplementing them reduces these problems. Evaluation of trace mineral levels in the diet is a routine recommendation for cattle with hoof problems, including laminitis, even in the very mainstream Merck Veterinary Manual:

<http://www.merckvetmanual.com/mvm/index.jsp?cfile=htm/bc/90514.htm&hide=1>

Note that high iron and/or sulfate in water interfering with trace mineral absorption is also mentioned.

While bovine medicine is way ahead of equine in appreciating and understanding mineral functions in the feet, it needs to catch up regarding laminitis. Cows do not normally have any absorbable glucose or starch because the organisms in their forestomachs ferment it before it can reach the small intestine. However, high grain feeding can result in some slipping through and even young calves are highly insulin resistant if fed too much free sugar. It is known that periods of high grain feeding are also when laminitis is most likely to occur. The high likelihood of a link between IR and laminitis in cattle opens another realm for possible negative effects from high iron because iron overload worsens insulin resistance and insulin resistance increases iron absorption.

Selenium is always thought of in terms of toxicity to the feet, but selenium can also contribute to hoof health. Selenium is incorporated into glutathione peroxidase enzyme, an important antioxidant for protecting the fats. Vitamin E is important for the same reason.

Manganese plays no real direct role in hoof health, except as manganese SOD enzyme that functions inside the mitochondria.

A deficiency of vitamin A is unlikely, but if it did exist it could slow hoof growth. Vitamin A binds to receptors that stimulate cell division. As mentioned above, E is important to protect the fats.

© 2008 Eleanor M. Kellon, VMD

Since all of the B vitamins are involved in some way with protein, fat and carbohydrate metabolism and interactions, they play very important roles in a tissue as active as the hoof. Biotin gets the most attention because of some equine specific studies:

[Equine Vet J Suppl.](#) 1998 Sep;(26):51-7. [Links](#)

Effect of supplementary dietary biotin on hoof growth and hoof growth rate in ponies: a controlled trial.

[Reilly JD](#), [Cottrell DF](#), [Martin RJ](#), [Cuddeford DJ](#).

Department of Preclinical Veterinary Sciences, Royal (Dick) School of Veterinary Studies, University of Edinburgh, Summerhall, UK.

The effect of dietary biotin supplementation, at a dose rate of 0.12 mg/kg bwt, on growth and growth rate of the hooves of 8 match-paired ponies was investigated in a controlled feeding trial. Treatment animals had a mean hoof growth at the midline dead centre of the hoof capsule of 35.34 mm after 5 months of biotin supplementation compared to control animals 30.69 mm ($P < 0.05$). Comparison of regression analysis also showed that biotin supplementation produced a significantly higher ($P < 0.02$) growth rate of hoof horn in this trial. Treatment animals had a 15% higher growth rate of hoof horn and 15% more hoof growth at the midline dead centre, after 5 months of biotin supplementation compared to control ponies. No differences were found between feet for growth of horn, but the older animals in the trial had significantly lower hoof growth ($P < 0.05$) than the remaining ponies.

[Equine Vet J.](#) 1995 May;27(3):183-91. [Links](#)

Comment in:

[Equine Vet J.](#) 1995 May;27(3):166-8.

Histological and physical assessment of poor hoof horn quality in Lipizzaner horses and a therapeutic trial with biotin and a placebo.

[Zenker W](#), [Josseck H](#), [Geyer H](#).

Institute of Veterinary Anatomy, University of Zürich, Switzerland.

This paper represents the second part of a study searching for factors which could be responsible for an inferior hoof horn quality of the Lipizzaner horses of the Viennese Spanish Riding School (SRS) noticed in the late 1980s. It includes an evaluation of a treatment with biotin and 42 Lipizzaner horses were tested in a double blind study. The following parameters were evaluated: 1) the histology of the hoof horn in samples from the bearing border 2) the tensile strength of the coronary horn in bearing border samples and 3) the influence of biotin upon the histological changes and the tensile strength after application of 20 mg/day of biotin during 38 months. The histological alterations of bearing border specimens were assessed by use of a grading system (Grade 0 = unchanged; Grade 1 = slight changes; Grade 2 = moderate changes; Grade 3 = severe changes). Initially more than two thirds of the horses showed moderate to severe changes: microcracks visible in the transition from the middle to the inner zone of the coronary horn; separation of the sole from the coronary horn in the region within the white zone. The tensile strength of the coronary horn, with a mean of 39 N/mm², was 13 N/mm² lower compared with the unchanged hooves of 10 Warmblood horses, which were investigated by Küng (1991). After 19 months of biotin treatment, the horn quality showed a small but significant improvement. This could be shown by comparing the histological tissue structure before and after treatment, as well as treated animals vs. a placebo group.

[Equine Vet J. 1995 May;27\(3\):175-82. Links](#)

Comment in:

[Equine Vet J. 1995 May;27\(3\):166-8.](#)

Hoof horn abnormalities in Lipizzaner horses and the effect of dietary biotin on macroscopic aspects of hoof horn quality.

[Josseck H](#), [Zenker W](#), [Geyer H](#).

Institute of Veterinary Anatomy, University of Zürich, Switzerland.

This study involved a macroscopic evaluation of hoof quality in 152 Lipizzaner horses (130 from Austria and 22 from other countries) and a controlled double blind trial of the effects of biotin on hoof horn growth and quality over 19 months in 42 stallions from the Spanish Riding School (SRS) in Vienna. Using a grading system that incorporated evaluation of horn wall, white line, sole and frog, the macroscopic study revealed the following: 90% of the Austrian Lipizzaners had soft white lines and crumbling, fissured horn at the bearing border of the walls; 39% of the stallions of the SRS, > 4-years-old, had medium to severe hoof horn changes. Daily administration of 20 mg biotin to a test group of horses (n = 26) and a placebo to a control group (n = 16) showed that after 9 months the test group had significantly improved compared to the beginning of the trial and the placebo group (P < 0.01). In the test group, further improvement was observed during the following 5 months and, subsequently, the same good level of hoof condition was maintained over 3 further years of observation. Growth rate of the horn wall was equal in the biotin and placebo group, being 7 mm/28 days, giving a wall renewal period of 11 months. Mean plasma biotin level of untreated horses was 350 ng/l; plasma levels of biotin supplemented horses were > 1000 ng/l. It was concluded that continuous dietary supplementation with biotin at a daily dose of 20 mg is indicated to improve and maintain hoof horn quality in horses with less than optimum quality hoof.

The long-term influence of biotin supplementation on hoof horn quality in horses.

[Geyer H](#), [Schulze J](#).

Institute of Veterinary Anatomy, University of Zürich.

The influence of dietary biotin in horses with brittle hoof horn and chipped hooves was investigated in a long-term study, which was performed over a period from one to six years. 97 horses received 5 mg of biotin per 100 to 150 kg of body weight, per os, daily; 11 horses were not supplemented with biotin and served as controls. The hooves of all horses were evaluated macroscopically every three to four months. Hoof horn specimens of the proximal wall were examined histologically and physically in 25 and 15 horses, respectively. The tensile strength of normal coronary horn was 60 N/mm² or greater; it was reduced in areas of histological alterations, the lowest value being 20 N/mm². The hoof horn condition of the biotin-supplemented horses improved after eight to 15 months of supplementation as determined by macroscopic and histologic examinations. The hoof horn condition of most control horses remained constant throughout the study. The growth rate of the coronary horn of horses supplemented with biotin and of control horses was the same. The hoof horn condition deteriorated in 7 of 10 horses after biotin supplementation was reduced or terminated. It was concluded that biotin should be continuously supplemented at the full dosage in horses with severe hoof horn alterations.

It's not just horses that have hoof/horn/claw problems with biotin deficiency. There's no question that inadequate biotin can result in hoof problems, but it's rarely going to be the only problem, and will not completely correct all hoof quality issues. This study gives a little bit of insight into biotin's action:

[Pharmacologic effects of biotin on epidermal cells]

[Article in German]

[Fritsche A](#), [Mathis GA](#), [Althaus FR](#).

Institut für Pharmakologie und Biochemie der Veterinärmedizinischen Fakultät, Universität Zürich.

Biotin deficiency in animals causes pathological changes of the skin and its appendages including, for example, exfoliative dermatitis, depigmentation, and alopecia. The hooves of

biotin-deficient swine are weak, brittle, and often necrotic. These changes disappear after dietary biotin supplementation. Biotin supplementation also noticeably improves the hoof quality of horses, cattle and swine having no apparent biotin deficiency. In order to elucidate the molecular basis of these effects, the influence of biotin on cytokeratin expression in a keratinocyte cell line (Ha-CaT) was investigated using electrophoretic and immunological techniques. Pharmacological biotin concentrations of 1 microM, and 100 microM in the culture medium caused a specific increase in cytokeratins, which are normally induced upon terminal differentiation of epidermal cells in vivo. The expression of cytokeratins occurring in stratified epithelia independent of differentiation were not affected. These findings show that biotin directly stimulates the differentiation of epidermal cells. Such a molecular mechanism revealed in cell culture could provide an explanation for the therapeutic effects of pharmacological doses of biotin on hoof quality in farm animals.

However, biotin is also essential for the synthesis of long chain fatty acids and may also be contributing that way. Loose white line connections is the hallmark of biotin deficiency in cattle. Most studies have used 20 mg/day for a full size horse.

High grain feeding in cows is known to decrease the pH in the rumen and decrease synthesis of biotin by the bacteria. The same likely occurs in horses. Because we don't know how heavily the horse relies on synthesized biotin versus biotin in the diet, I routinely supplement with 10 mg/day in horses being grain fed – just in case!

A horse on a heavily forage based diet is unlikely to be deficient in B vitamins. On the other hand, it certainly isn't far fetched to suspect poor hoof quality could sometimes be a marker of inadequate B vitamin intake. Because of the high concentration of protein in the hoof wall, the Bs most involved in protein metabolism should probably get special attention. This includes biotin, pyridoxine, folic acid and B12. No evidence whatsoever exists for B12 or folic acid deficiencies in horses. Because of folic acid's key role in nitric oxide generation, critical for keeping blood vessels open, I do often supplement it in insulin resistant horses but otherwise the B in that group with the least available information is pyridoxine. The equine requirement for pyridoxine has never been established or even estimated, which makes it difficult for me to feel comfortable that it can be ignored. (Also interesting that an early symptom of pyridoxine deficiency in people is burning feet.) Supplementation with 100 to 200 mg/day of pyridoxine is conservative and reasonable.

To summarize the **most common deficiencies** that will impact the hooves:

- Crude protein
- Sulfur containing amino acids (methionine primarily, cysteine)
- Essential fatty acids
- Zinc
- Copper
- Selenium
- Vitamin E
- Biotin
- ? pyridoxine

© 2008 Eleanor M. Kellon, VMD

Feral horses have a major advantage over domesticated when it comes to their diet. They typically range over a large area of land, which is likely to represent several different soil types and certainly many different types of vegetation. When the horse consumes a variety of plants growing in a variety of different soils, it gets a generous supply of essential fatty acids, B vitamins and is far more likely to receive the amino acids and minerals it needs since each plant's profile will be different.

Stabled domestic horses often eat precisely the same meals, same hay types, every day of their lives. Even horses fortunate enough to be pastured have much less plant variety than a feral horse, and the mineral profiles, especially the trace minerals iron, copper, zinc, manganese and selenium, are likely to be very similar in all the plants because they growing on the same soil.

I see hay and pasture analysis results from all over the world, USA, EU, Australia, New Zealand, and tropical locations. With very few exceptions, the common deficiencies are precisely the ones that are listed above. Many commercially available hoof supplements do a far better job at coming close to correctly balancing common equine diets than the multi-ingredient vitamin and mineral supplements do. This is because they target the common deficiencies better, without adding more of minerals that the horse does not need and which will actually make deficiencies worse.

The reason nutritional deficiencies show up in the hoof so often is simply that it is a very metabolically active tissue. The horn is being worn away and must be replaced constantly. If the horse is lacking one or more of the nutrients it needs to do the job, the hoof quality will suffer. All key nutrients must be present in correct amounts.

My advice to any of you who suspect you may be dealing with hoof problems that have a nutritional component is to have your hay or pasture analyzed then work with an equine nutritionist to provide only the nutrients your horse truly needs to have a balanced diet. Excesses are as harmful as deficiencies since they may crowd out the nutrients that are in low concentration. When approached in this way, not only are results far superior but your costs will be lower as well. Best of all, you are not only feeding your horse's feet, you are correctly feeding every cell in your horse's body.

The horse's feet are a sensitive indicator of nutrition overall.