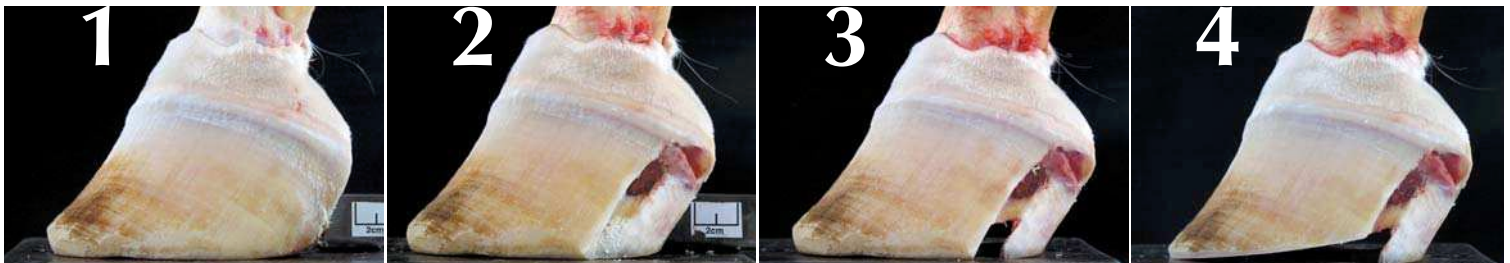


Research

Uniform Sole Thickness

By M.T. Savoldi, G.F. Rosenberg

Researcher Explains How to Define a Heel



When UST is not maintained, adverse changes occur. Photos courtesy of Michael Savoldi.

During 28 years as the resident farrier at California State Polytechnic University at Pomona, I found that, by trimming to “uniform sole thickness,” the true foot reveals itself so that form and function are optimal regardless of breed or confirmation. Horses go better and stay better. Uniform sole thickness (UST) defines the plane of the hoof capsule. That is to say, the sole, at each point of connection to the hoof wall is of equal thickness from heel to toe. When uniform sole thickness is not maintained, adverse changes occur. My work has shown these results to be consistent.

In this and future articles, I will present a series of photos documenting the progressive stages of a dissection of the horse’s hoof. This hoof is representative of the thousands of feet I have dissected. It serves to illustrate the principles of trimming to a uniform sole thickness. In this first article, I will focus on the heel.

There seems to be general agreement as to toe length. Everyone’s opinion will be slightly different, but, overall, a group of professional farriers will look at a foot and arrive at some consensus with regard to toe length. However, with regard to length of heel, there is wide disagreement.


What I have found to be the case is that, in order to establish uniform sole thickness, the heels should be taken down to the junction of dead and live tissue in similar fashion to the treatment normally given to the toe area. Put simply, it doesn’t matter how far down or how far back you take the toe if you leave too much heel. Hopefully, the following photos will help to illustrate this point.

Fig 1. From this angle, it is difficult to determine much about the foot. There appears to be a dish in the toe which might indicate an excess of toe length. Traditionally, it has been thought that when the angle of the toe, the angle of the heel, and the angle of the first, second, and third phalanx (PI- PIII) line up, the foot is in correct trim. It appears as though the toe and the heel angle line up pretty well on this foot.

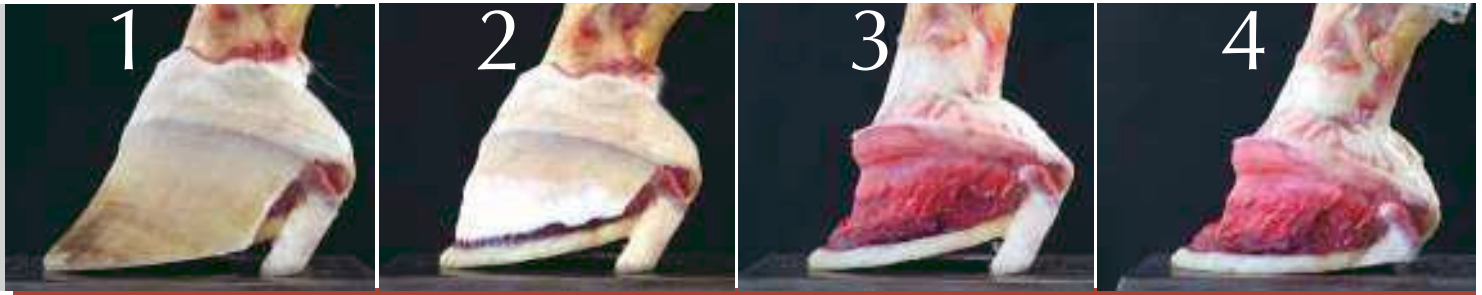
Fig. 2. A window into the foot reveals three layers of tissue. Dead, or necrotic tissue appears white and chalky. Above this there is healthy living sole, yellowish in color and more waxy in appearance. A final layer of sensitive lamina is reddish in color. Here, it begins to become apparent that, although our angles appear to be “correct” there is an excess of heel on this foot.

Fig. 3. Removing the first layer of necrotic tissue reveals a layer of living, healthy sole. With this tissue now removed, it is more apparent that there seems to be excess wall length in the heel below the level of the live sole. This excess heel dramatically changes the mechanics of the foot.

Fig. 4. In this final frame, the wall has been trimmed parallel to, and at the level of, the live sole to establish uniform sole thickness, leaving the excess wall length in the heel. It should now be quite apparent that, contrary to what might have been initially obvious, the length in this foot is not so much in the toe as it is in the heel. Although the hoof has been trimmed to uniform sole thickness, the plane of the hoof capsule remains elevated by the excess of wall length in the heel area. Unless this excess length is removed, body weight will continually cause movement of tissue, creating flares and possibly causing the sole to drop.

In the next article of this series, I will continue the dissection of this foot and discuss distortion of the sole and soft tissue damage based on the plane of the hoof capsule. In the third article, I will continue with pathology based on the plane of the pedal bone (PIII). 

Uniform Sole Thickness (II)



Notice the progressive dissection of the hoof capsule, illustrating pathological changes that occur when UST is not maintained.

Horses benefit from establishing and maintaining UST.

Story and Photographs by M.T. Savoldi, G.F. Rosenberg

This is the second in a series of three articles that attempt to convey the importance of trimming to uniform sole thickness (UST). The photographs show the progressive dissection of the hoof capsule to illustrate pathological changes that occur when UST is not established and maintained. We hope that this series of photos will clarify the importance of establishing UST.

This article illustrates three points:

- Horses are well-served by establishing and maintaining UST.
- The pedal bone (P3) moves within the hoof capsule creating sole flexion. When there is excess hoof wall, the sole deforms to such a degree that the P3 bone “seeks out” the level of the horizon.
- When UST is not established and maintained, the hoof capsule and the sole distort, and, over time, P3 remodels.

Fig. 1. This hoof has been trimmed to UST. I have left the original length of wall in the heel area. I hope it is apparent that the heels are too long. Also, notice the compression rings within the hoof wall of the toe. Distortion in the toe area shows flattening and flaring of the toe on the

hoof capsule.

Fig. 2. I have removed the distal portion of the hoof wall. Notice that the sole has uniform thickness (aside from the excess length of wall in the heel that was left for illustration). The unsound nature of the original trim should now begin to be apparent. Imagine this hoof under load – something will have to give. The heels are going to collapse, or the sole will have to bend, or both. How the hoof reacts to excess length of wall depends on a variety of factors, including confirmation, the size of the animal and how the animal moves.

In comparing Fig. 2 to Fig. 1, it should be apparent that the toe flare is actually caused by excess wall length in the heels. Again, imagine this hoof under load; each time the horse takes a step, P3 is “jammed” forward and downward causing the sole to flatten and the toe to flare out. When a hoof is trimmed to UST and regular shoeing intervals are maintained, there are no toe flares to speak of.

Fig. 3. This frame illustrates several points. First, notice the shape of the sole. There is a flattening in the toe area. The heels have also been pushed up. The result is that the P3 is essentially being suspended between these points, causing

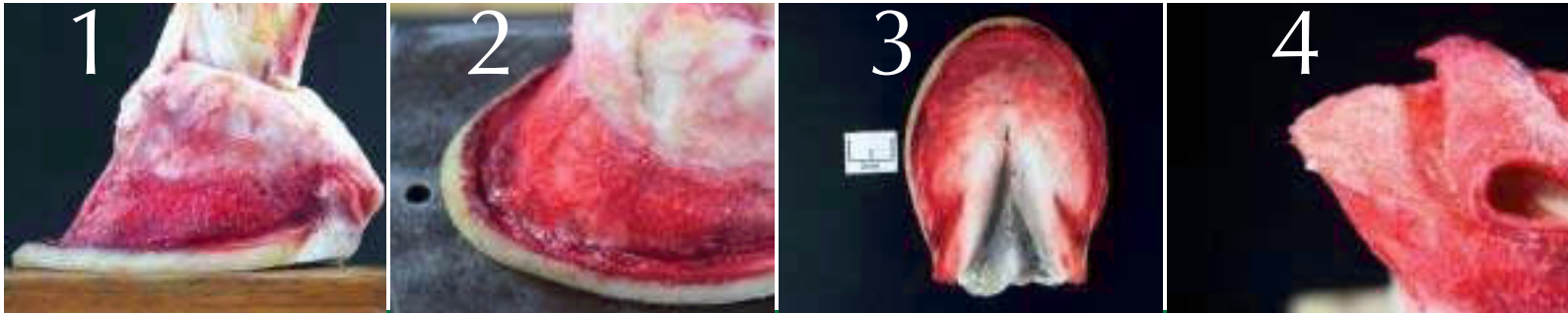
an unnatural curvature to the sole.

Fig. 4. In the final frame, the excess length of wall in the heel area has been removed. The hoof capsule is now on the same plane as the horizon. Observe the space between the heel and the ground surface. This is distortion in the heel. The sole is in an upward bend. One of the many advantages to UST is that distortion of the sole can be easily recognized. Our goal for trimming of UST is to remove distortion to the sole. When shoeing for distortion of this type, place a level shoe on the foot so that the heels float, and let the sole level to the shoe. The sole will level to the shoe very quickly. How quickly will depend on several factors, including moisture content of the hoof and the severity of the distortion. Leave the frog intact to provide sole support and assist with blood circulation.

The next article in this series will continue the dissection of this foot and discuss pathology based on the plane of the pedal bone.

Note to reader: These methods work well for some, but are not the only way to achieve soundness. 🐾

Uniform Sole Thickness (III)



The hoof depicted here shows the result of not trimming to uniform sole thickness.

Trimming to UST promotes hoof health.

Story and Photos by M.T. Savoldi, G.F. Rosenburg

In the previous two articles in this series, we demonstrated how to analyze a hoof trimmed to uniform sole thickness (UST). In this article, we will demonstrate pathology based on the plane of the bone that arises in a foot not trimmed to UST. If a hoof is trimmed other than to UST, the sole and the pedal bone (PIII) will distort. The sole will flatten, and PIII will remodel.

The photographs in this article emphasize the final stages of dissection. PIII has remodeled, and the soundness of the animal has been compromised.

Fig. 1 This frame shows a foot that has had the hoof wall removed. The toe area of PIII is pushing into the sole, causing the sole to sag and the bone to degenerate. Think about the dynamics that would cause this type of pathology. Trimming with excess length of wall in the heel positions the bone for this type of remodeling. For illustration, imagine a human foot in a cowboy boot; the raised heel causes internal pressure in the toe and affects the muscles and ligaments.

Fig. 2 This frame depicts the same hoof from a slightly higher angle focus-

ing on the toe. PIII has remodeled so that the leading edge of the bone has been pushed upward (lipped). This type of lipping has two possible causes: excess of wall length in the heel or a very steep arch under the palmer process, or both. In both cases, trimming to UST will minimize the lipping.

Fig. 3 Looking down on the proximal surface of the sole, note the darkened area in the toe. This is sole bruising. Clinical signs show that PIII is weight-bearing in the toe in this foot. The discoloration is from internal pressure of PIII and nerve damage. Note: This sole soreness is a result of downward movement of PIII in the toe as opposed to pressure resulting from the shoe or ground surface.

Fig. 4 After removing the dermis to expose the solar surface of PIII, we can see where PIII has flattened, degenerated and is losing vertical depth. Also, note the lipping in the toe.

This case is typical, but it is not a severe example of the distortion to PIII that occurs when a hoof is not trimmed to UST. If a hoof is continually trimmed so that UST is not maintained, the forces on PIII will

cause remodeling.

We know that the plane of the hoof capsule is set by trimming to UST, but the plane of PIII is defined by the angles of the sole. The sole seeks to be on a plane with the horizon, the level ground surface. Because the angle of PIII is dictated by the angles of the sole, PIII rarely will be level with the horizon. However we can best promote hoof health by understanding and trimming to UST so that the angle of PIII, and subsequently the entire bone column, is normalized.

As farriers, we need to learn to understand and accept what the foot is offering. We need to learn to work within the parameters of what is offered and not attempt to dictate what we believe the ideal foot would be in order to improve, develop and maintain a healthy foot.

Note: The AFA encourages the presentation of new shoeing and trimming methods and theories in Professional Farrier. The publication of these articles is not an endorsement of the particular theory nor should the lack of an endorsement by the AFA be misconstrued as criticism of the theory. 🐾